

Soft Tissue Sarcoma e-Contouring

Thomas F. DeLaney, M.D.

Chief, Sarcoma Service, Department of Radiation Oncology

Associate Medical Director, Francis H. Burr Proton Therapy Center

Massachusetts General Hospital

Andres Soriano Professor of Radiation Oncology

Harvard Medical School

DISCLOSURES

Author/editor: Elsevier (honorarium); UpToDate (honoraria), Inc; Wolters, Kluwer Health, Inc., (royalties)

Educational Conference Speaker: AO Spine (honorarium)

Educational Video Speaker: Oakstone Medical Publishing (honoraria)

Consulting: RBC Consulting(honorarium); Gerson Lehman (honoraria)

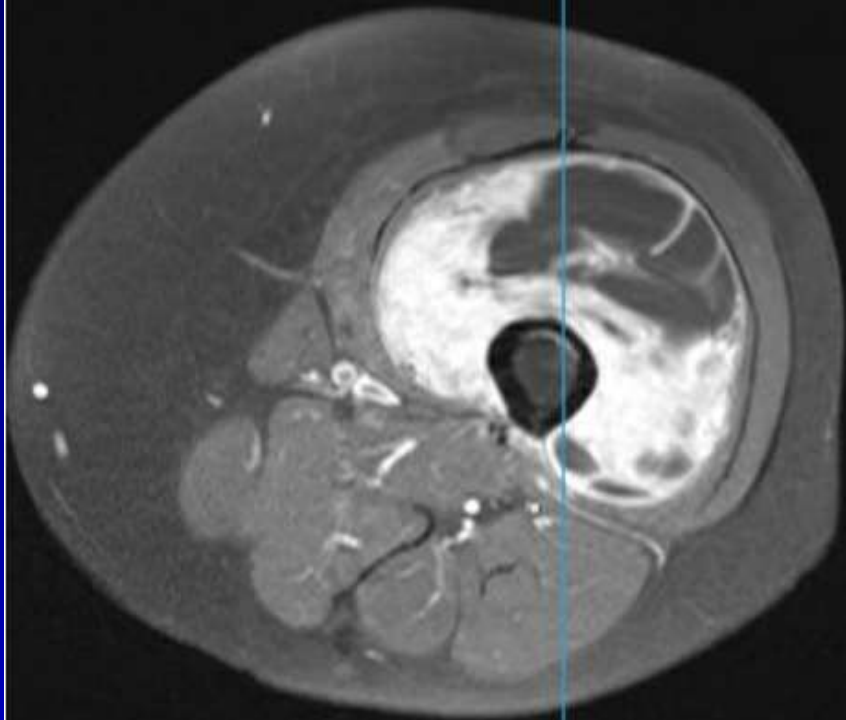
Medical Advisory Board: Chordoma Foundation (no remuneration)

LEFT THIGH UNDIFFERENTIATED PLEOMORPHIC SARCOMA

- 66 year-old presents with a palpable mass in her left thigh
- MRI showed a mass in the anterior thigh musculature, centered in the vastus intermedius, measuring 9 X 8.2 X 13.1 cm abutting and encasing 75% of circumference of the femur, which demonstrated associated cortical thickening, periosteal reaction, and some endosteal edema but normal signal intensity in underlying marrow.
 - Some associated soft tissue edema along the superior and inferior edges of the lesion
- Core biopsy showed undifferentiated pleomorphic sarcoma, grade 3/3.
- CT chest, abdomen, pelvis (-)

S POST (Series 10)

A



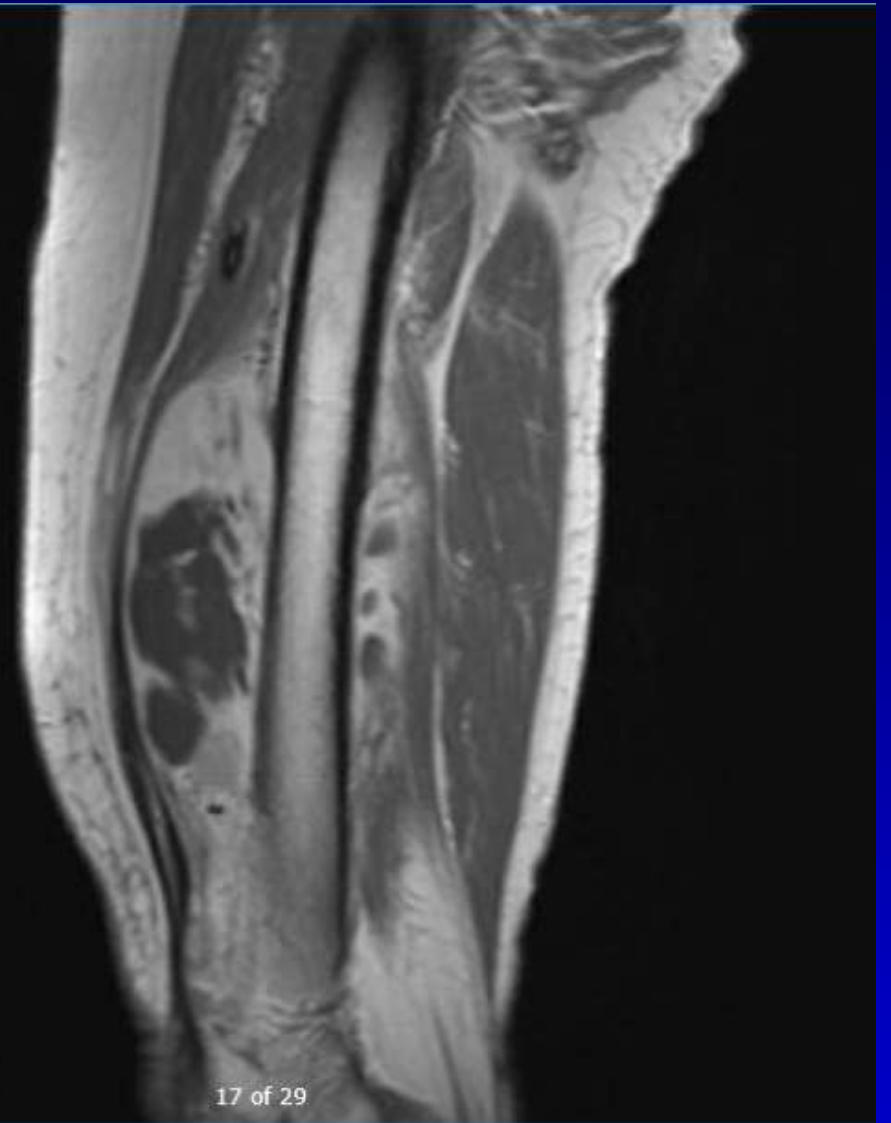
P

24 of 40

-43.27

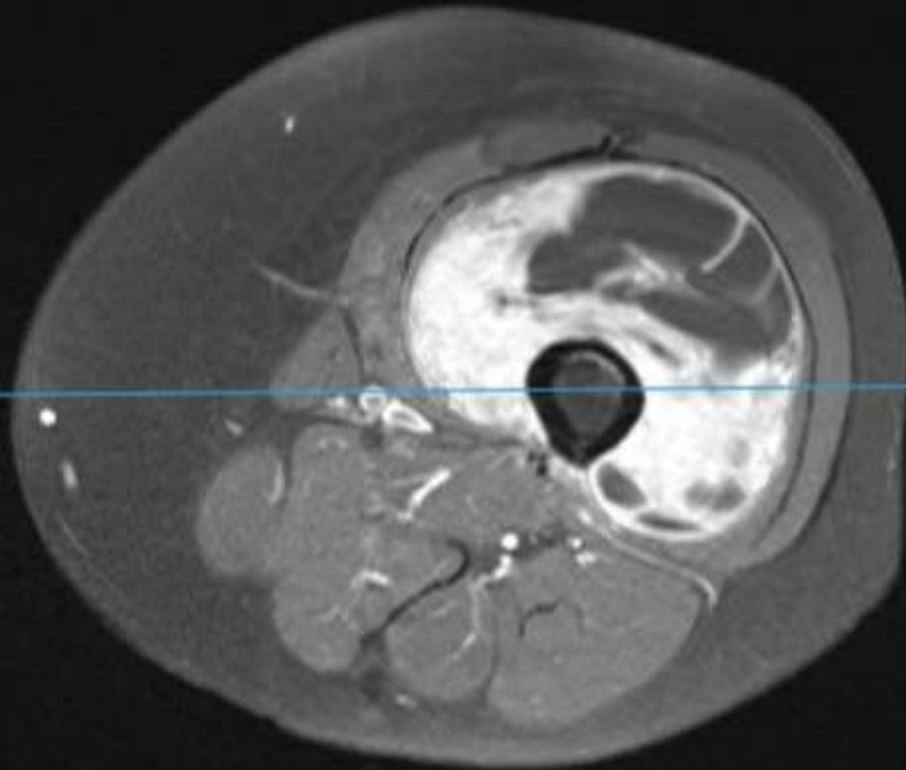
L

12: SAGT1 POST (Series 11)



17 of 29

T1 post-gadolinium MRI

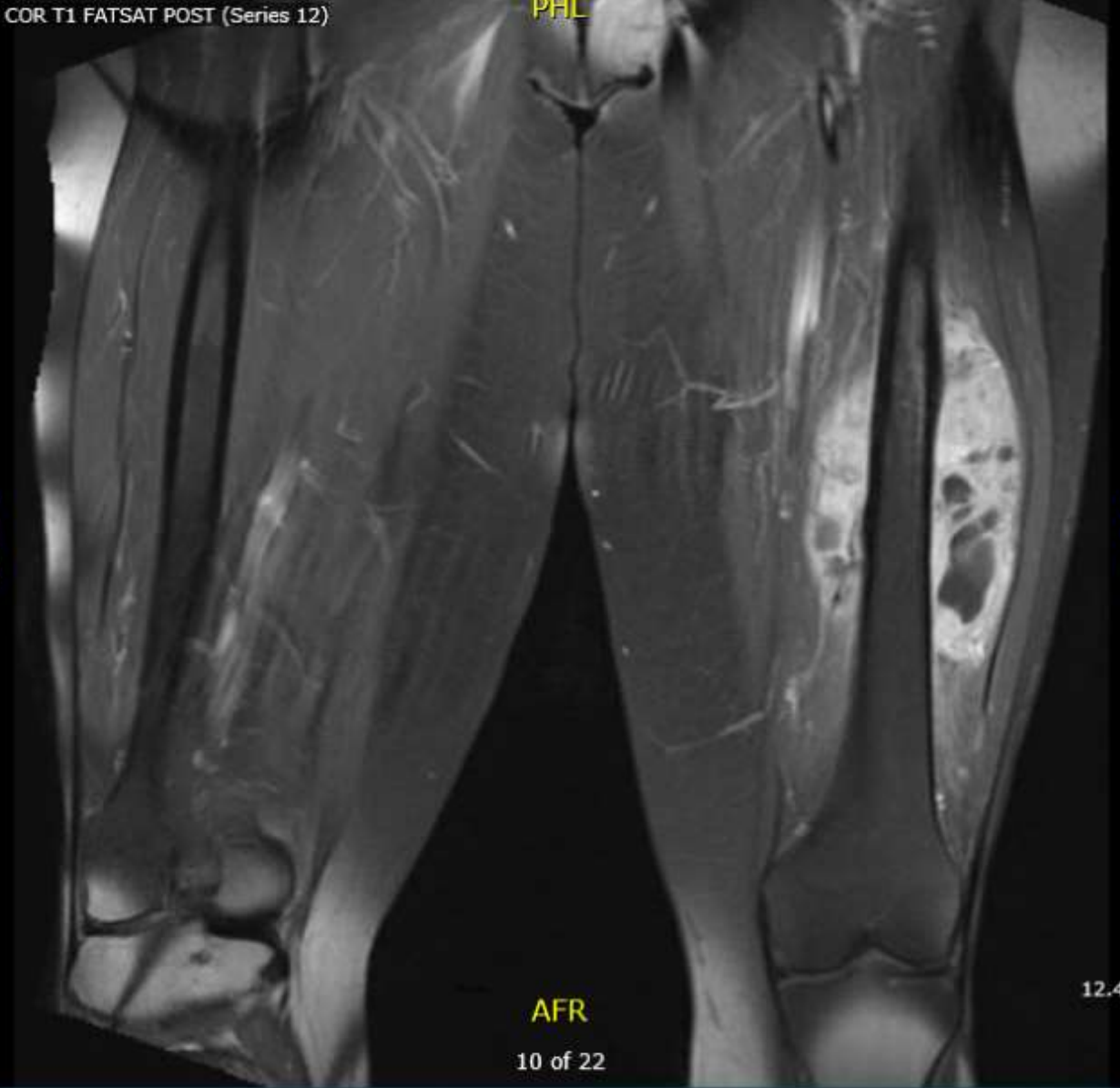


P
24 of 40

-43.27

L

P
R
H



AFR
10 of 22

12.45

A
L
F

T1 post-gadolinium MRI

LEFT THIGH UNDIFFERENTIATED PLEOMORPHIC SARCOMA

- Patient was entered on to SARC 032 study which randomizes patients (with UPS, dedifferentiated liposarcoma, myxofibrosarcoma) to preop RT 50 Gy/25 fx +/- pembrolizumab
 - She was randomized to the pembrolizumab arm
- She was treated with VMAT, 6 MV photons
- Preop restaging MRI showed interval decrease in the size of the mass to 7.1 x 8.1 x 11.4 cm with decreased internal enhancement.
- Underwent en bloc resection of tumor and abutting femur with intercalary endoprosthetic reconstructions
- Pathology: > 99% necrosis; (-) margins; tumor abuts but does not invade tumor

Preoperative RT

50 Gy/25 fx

VMAT

6 MV photons

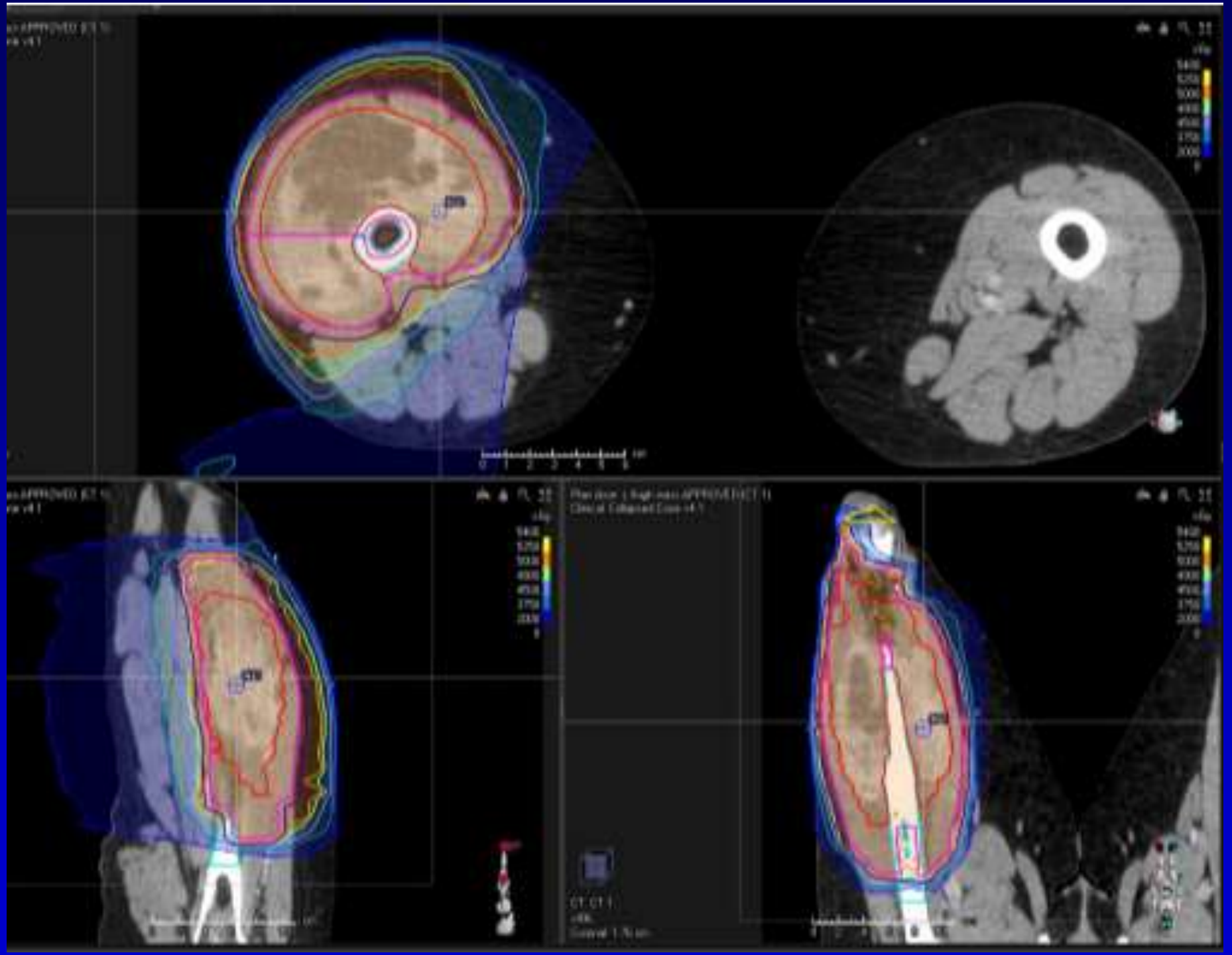
CTV1: GTV +
1.5 cm radial,
3 cm proximal/
distal margins

PTV expansion:

5 mm.

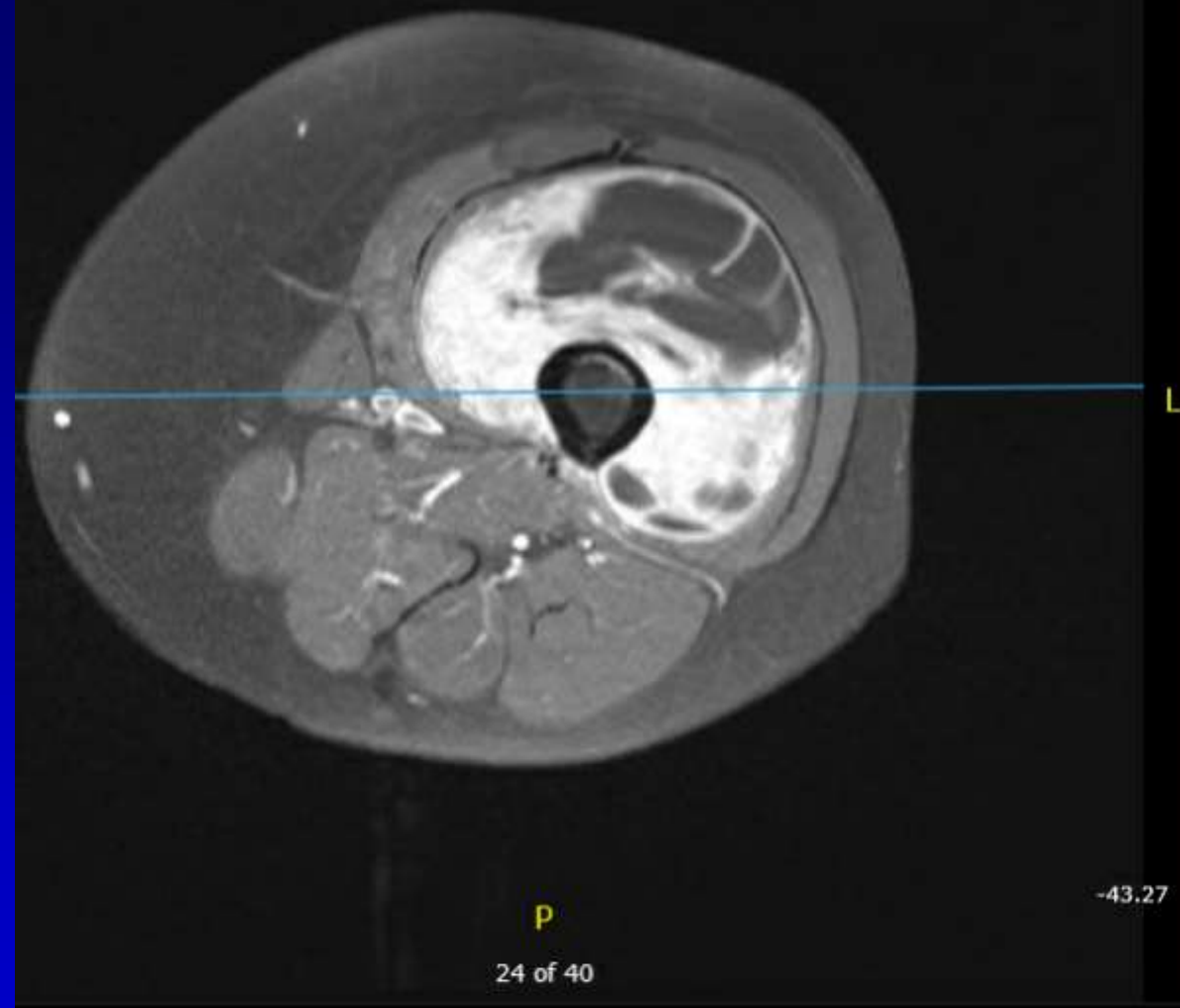
No bolus

Daily cone
beam



S POST (Series 10)

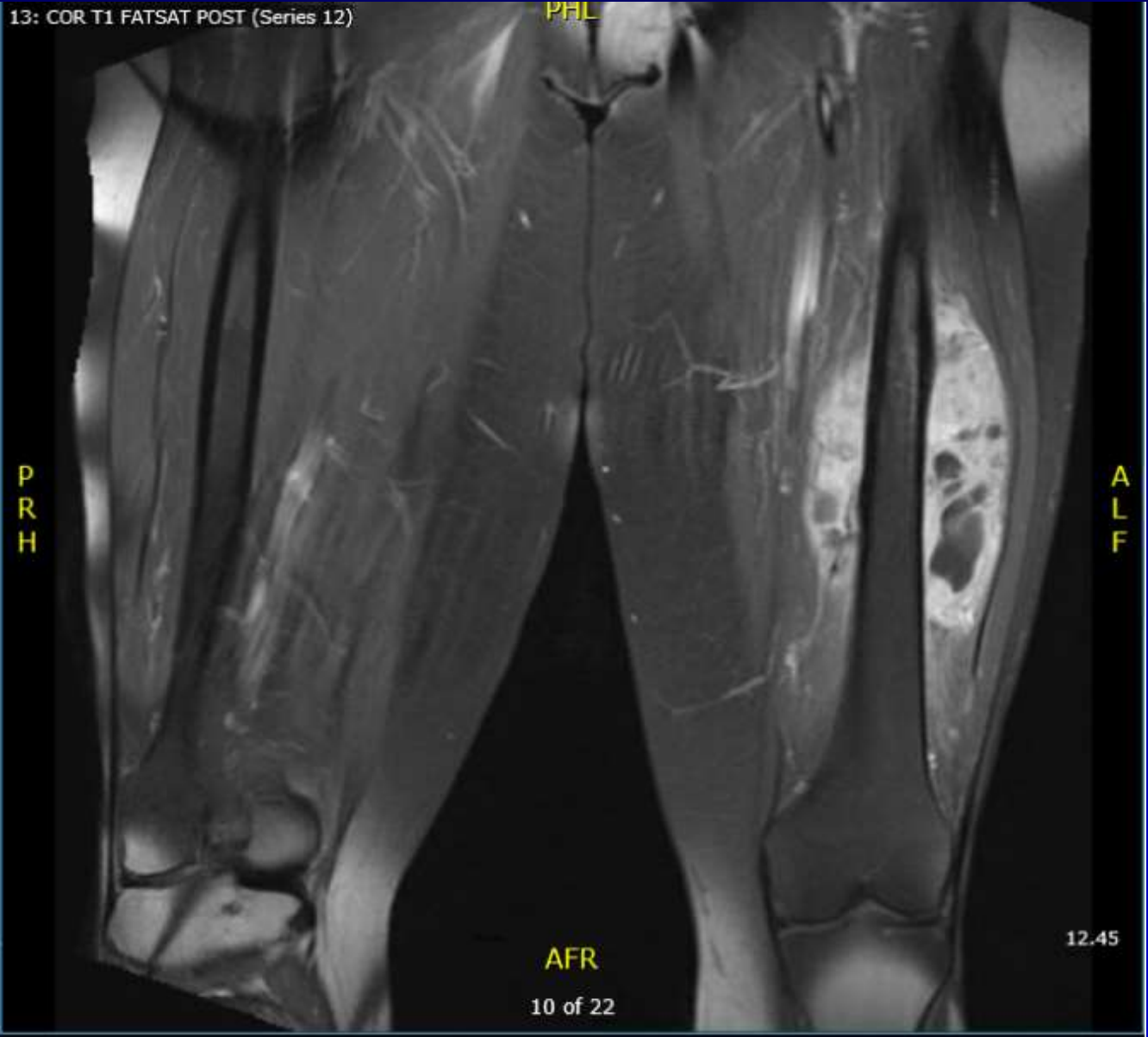A



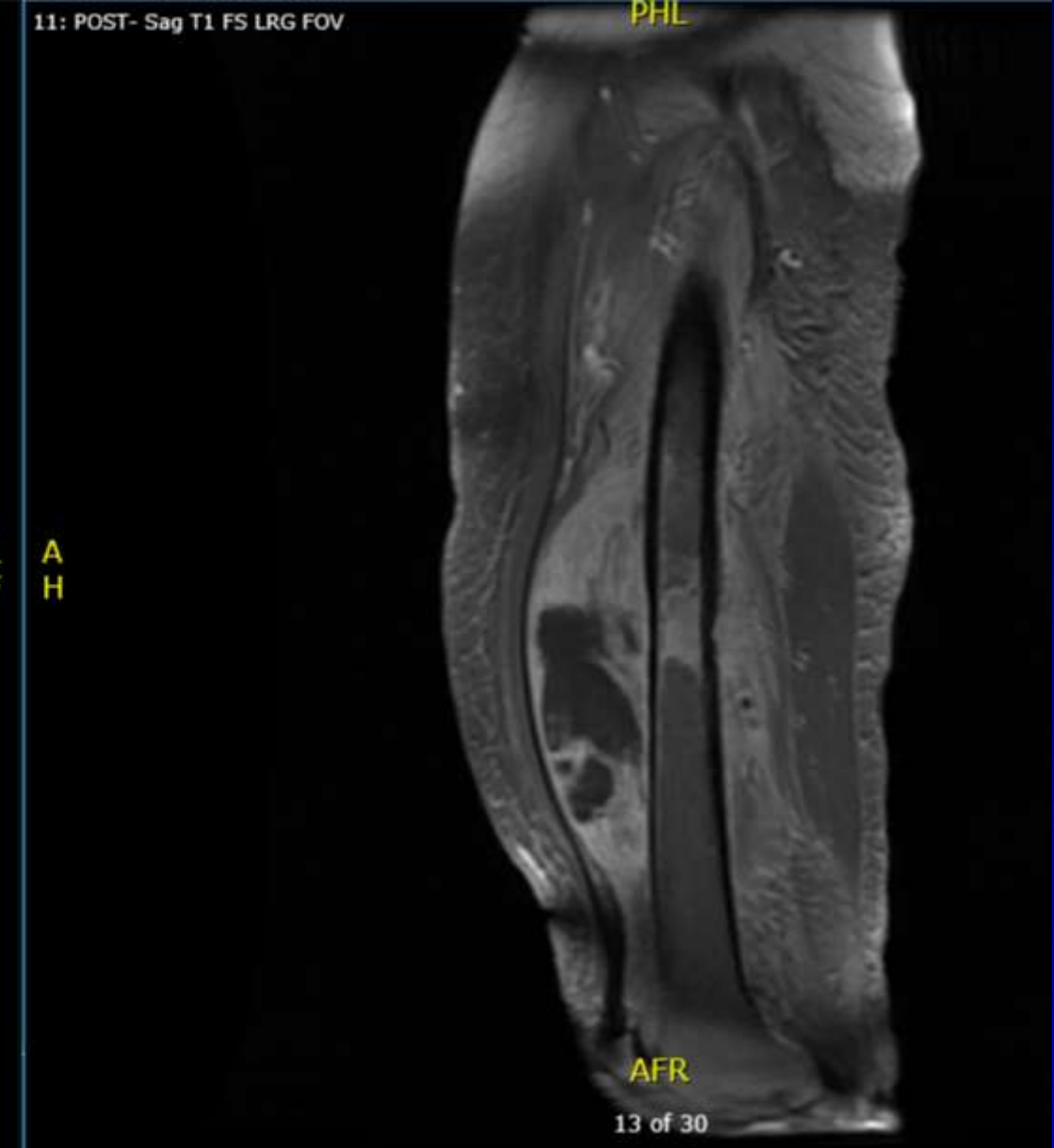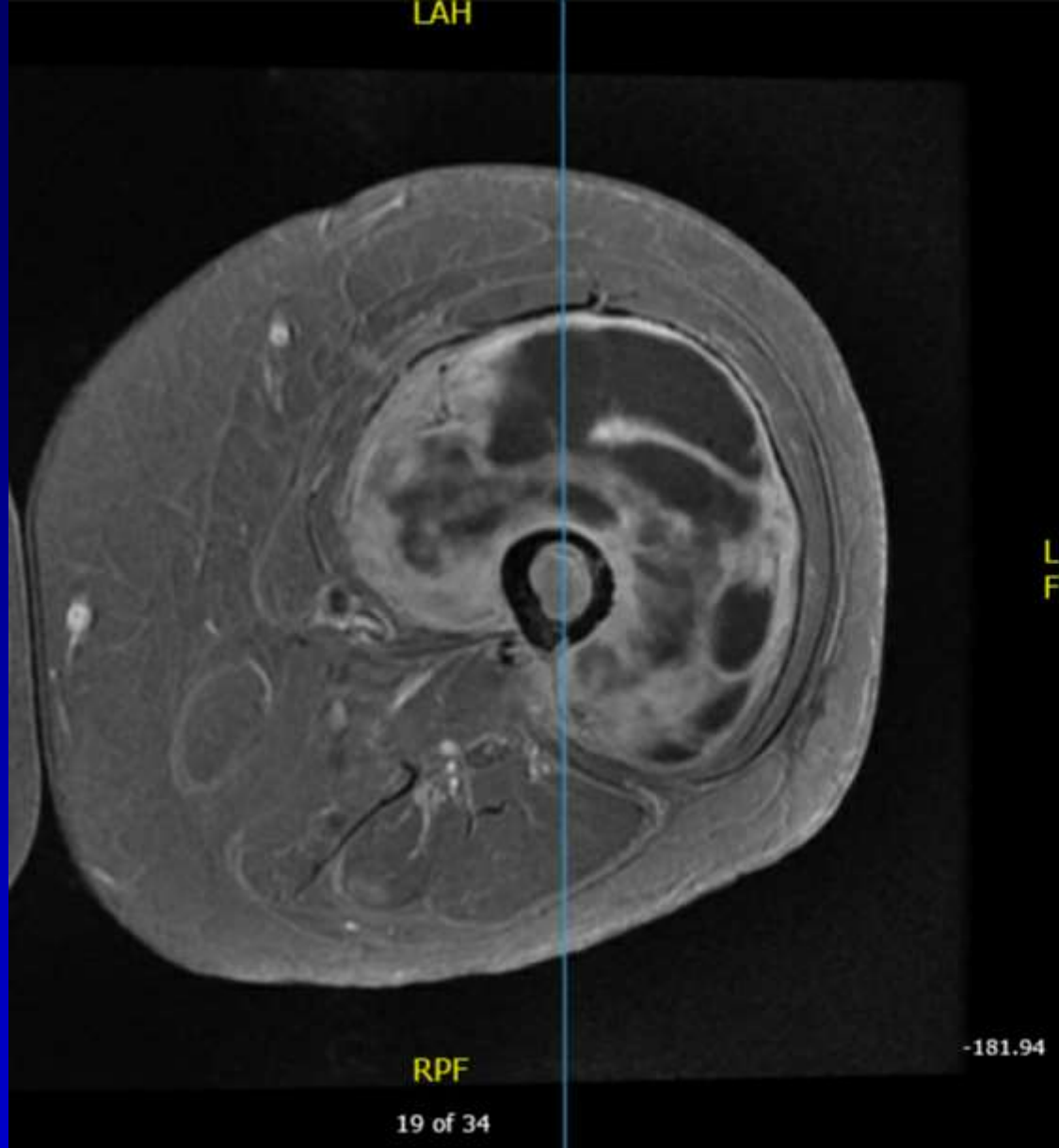
13: COR T1 FATSAT POST (Series 12)

PHL

L
P
R
H



T1 post-gadolinium MRI



L A
F H


T1 post-gadolinium MRI

RTOG 0630 PREOP RT TARGET VOLUMES

- GTV defined on the T1, post-gadolinium images
- For patients with G2, 3 tumors ≥ 8 cm
 - CTV 1.5 cm radial and 3 cm proximal/distal margins on the GTV + tumor-associated edema (confined to compartment)
- For patients with G1 or tumors < 8 cm
 - CTV 1 cm radial and 2 cm proximal/distal margins on the GTV + tumor-associated edema (confined to compartment)
- PTV expansion 0.5 cm if using daily image guidance

•

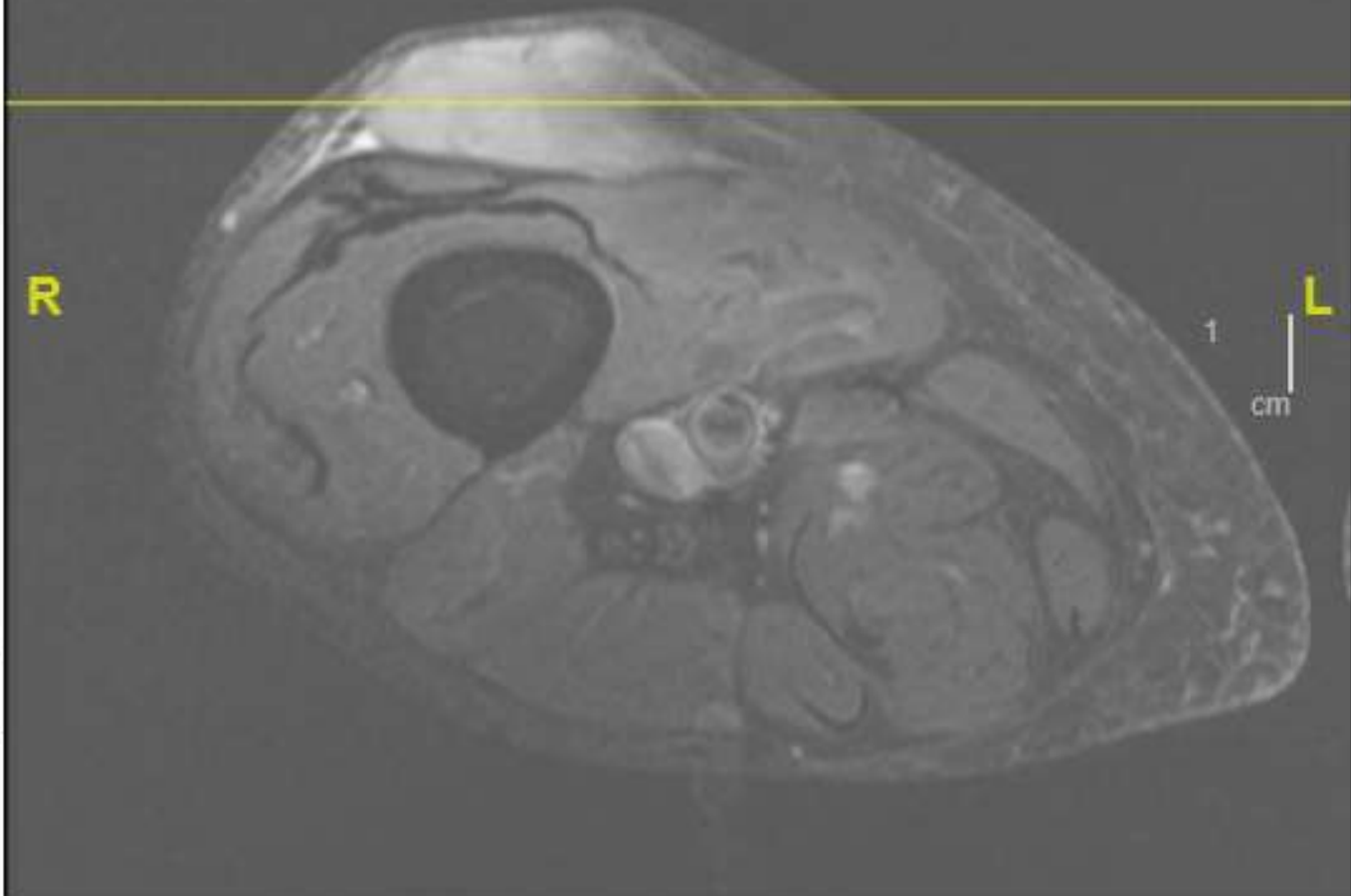
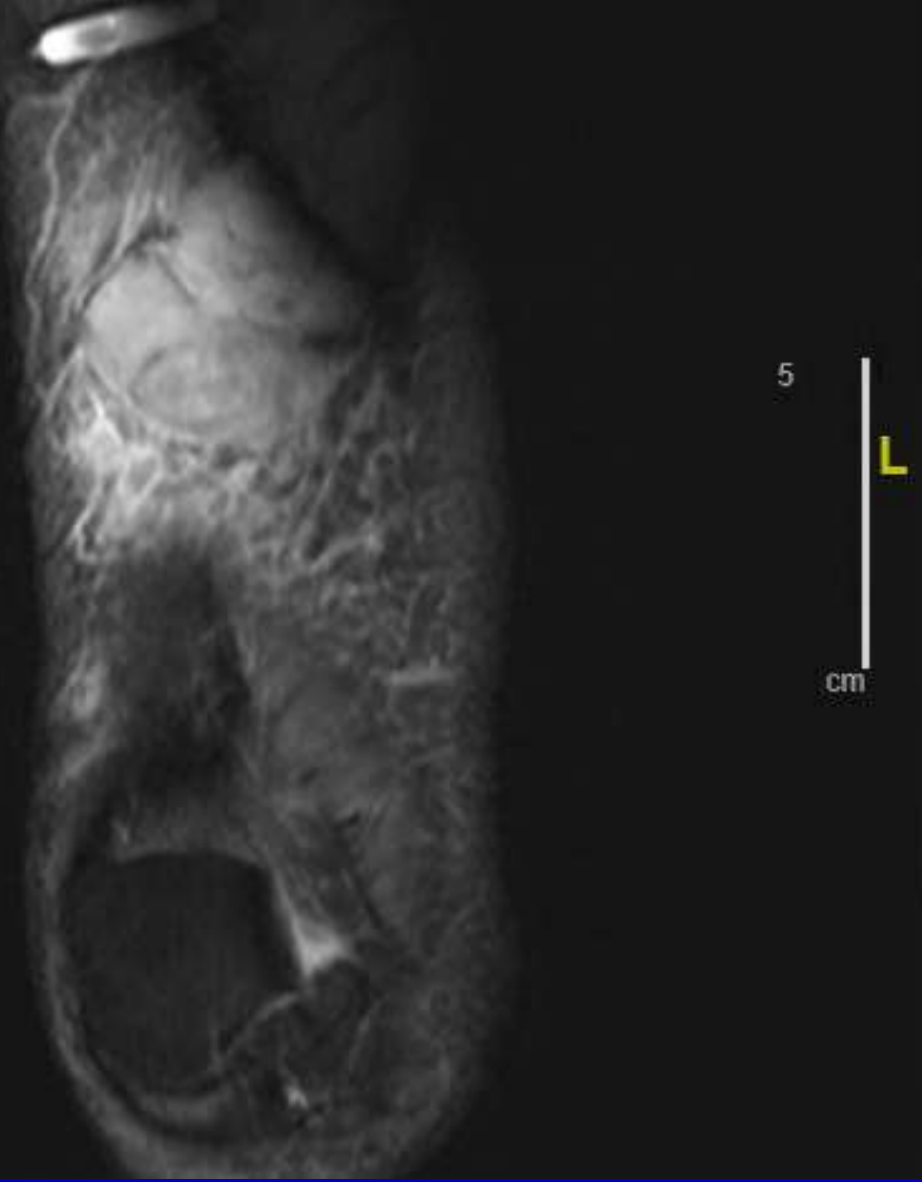
Wang et al, J Clin Oncol 2015 Jul 10;33(20):2231-8



THIGH SUBCUTANEOUS MYXOFIBROSARCOMA

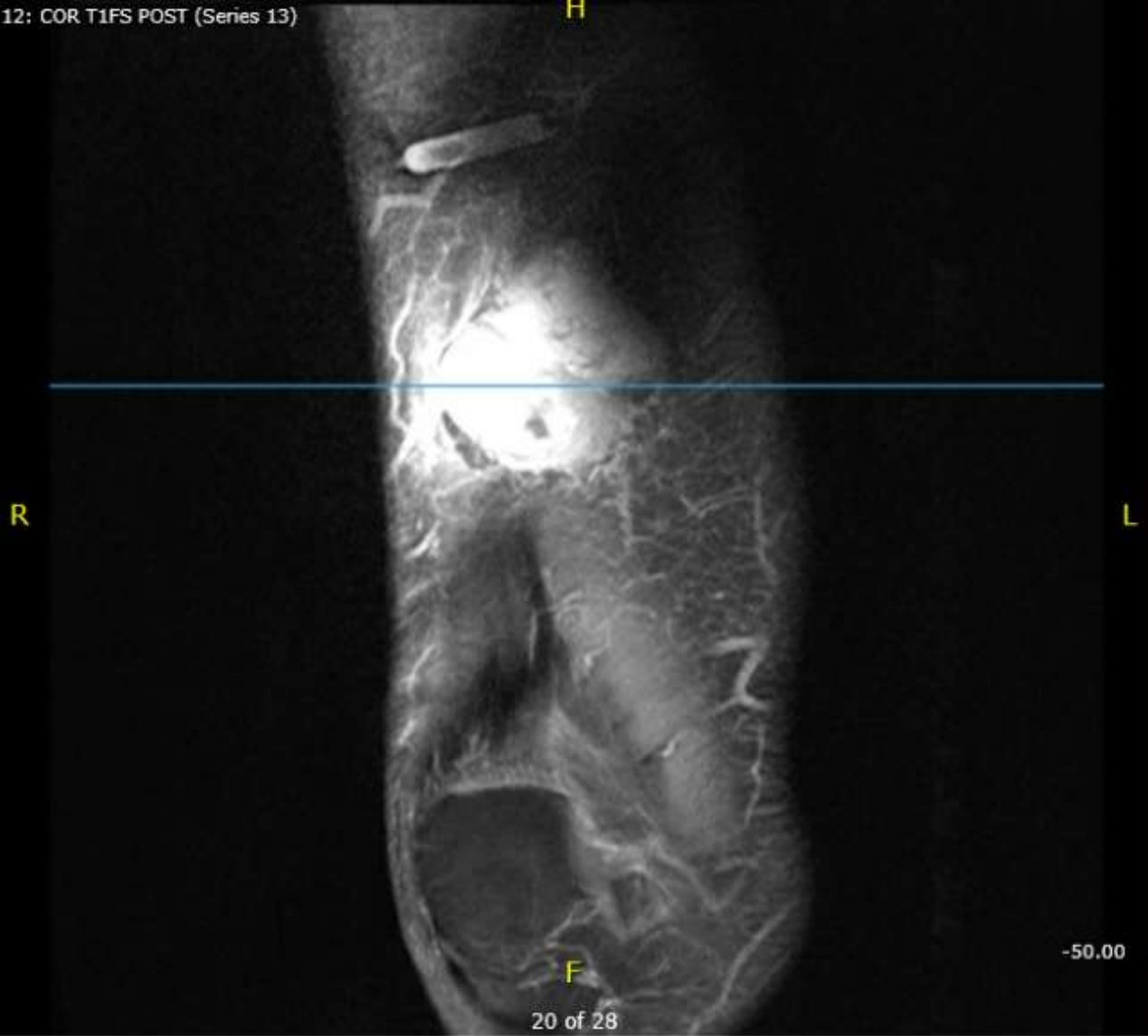- 82 year-old man notes a mass in anterior thigh
- US showed a heterogeneous predominantly hypoechoic ovoid subcutaneous mass with peripheral and possibly internal vascularity, measuring approximately 4.1 x 1.7 x 5 cm (TV x AP x CC).
- Mild adjacent subcutaneous edema is noted
- MRI showed slightly lobulated 4.4 x 1.9 x 4.5 cm subcutaneous mass anterior to distal femoral diaphysis. This lesion demonstrates mild heterogeneous enhancement. There is mild surrounding subcutaneous edema.

Se: 6
Im: 23

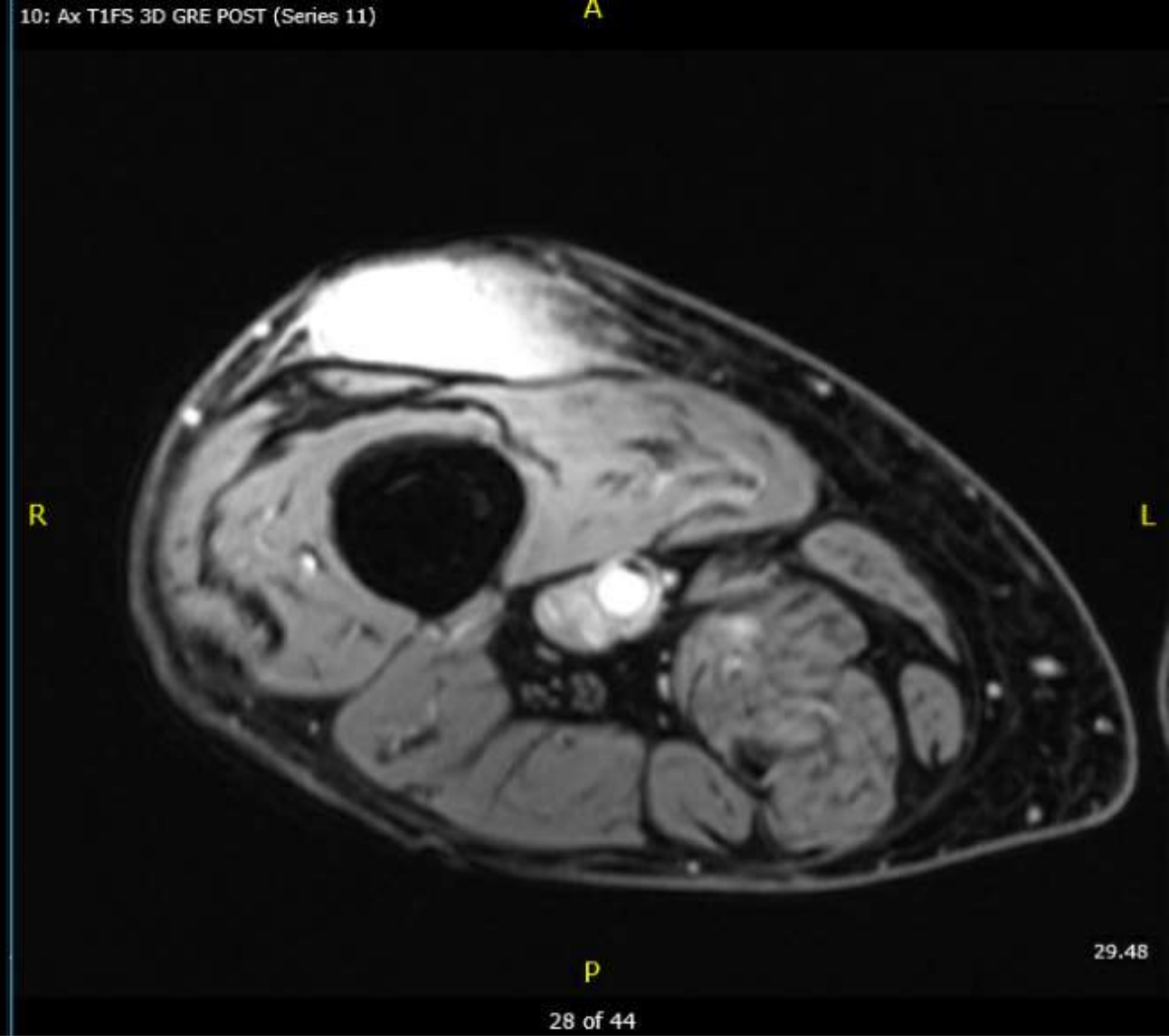


Coronal STIR and Axial PD FS MRI

12: COR T1FS POST (Series 13)

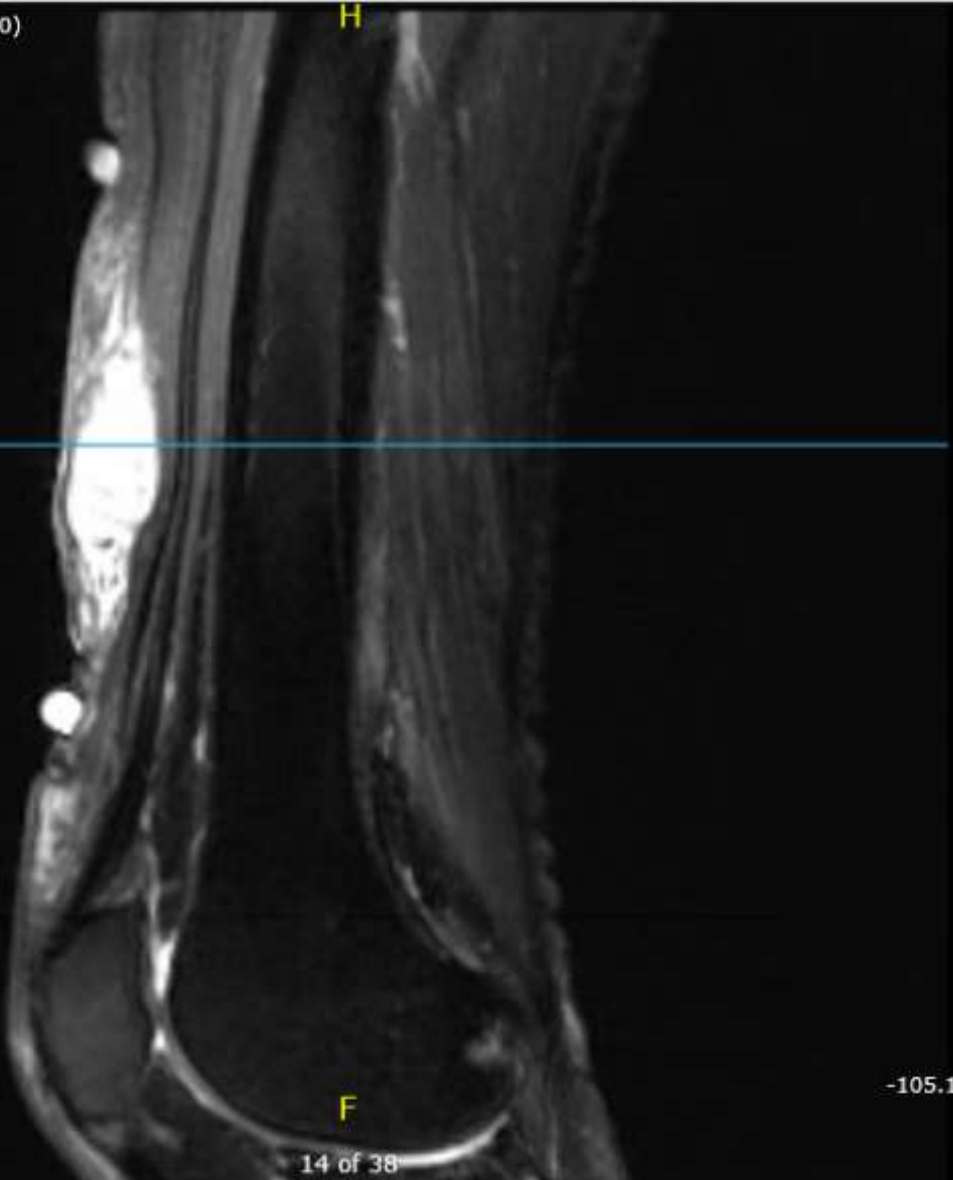


10: Ax T1FS 3D GRE POST (Series 11)



Coronal and Axial T1 post gadolinium MRI

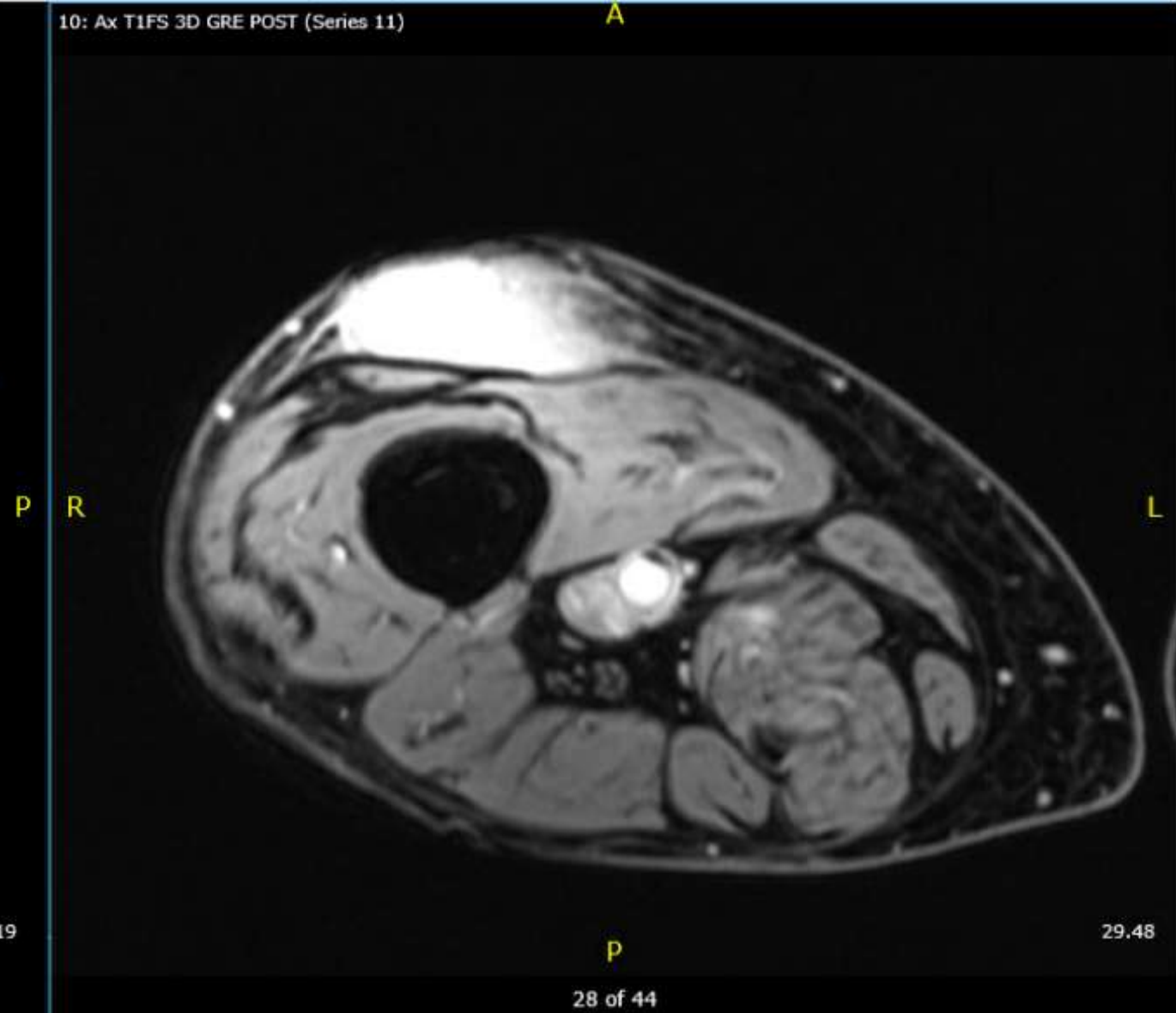
T2FS POST (Series 10)



14 of 38

-105.19

10: Ax T1FS 3D GRE POST (Series 11)



28 of 44

29.48

Sagittal and Axial T1 post gadolinium MRI

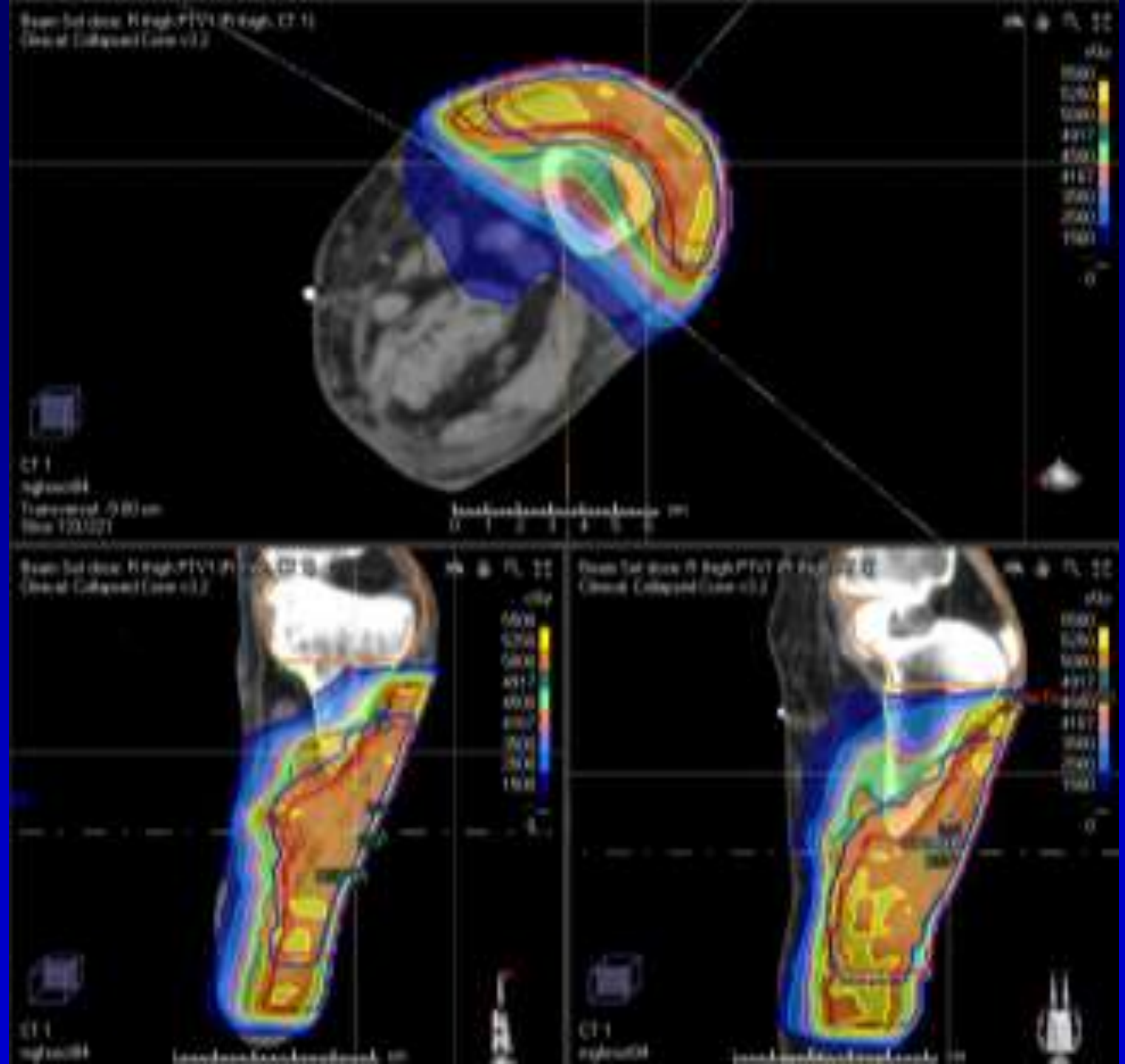
THIGH SUBCUTANEOUS MYXOFIBROSARCOMA

- Core biopsy shows myxofibrosarcoma, grade 2. No necrosis or LVI.
- Underwent en bloc excision with VAC dressing....confirmed (-) margins.
 - Pathology: 15.2 x 11.0 cm skin ellipse excised to a maximum depth of 0.9 cm
 - Tumor measured 6.2 x 3.9 x 1.9 cm
 - Margins: 4.2 cm proximal, 2.4 cm distal, 3.0 cm medial, 2.4 cm lateral, and 0.1 cm deep margin
- Right thigh closure with medial and lateral keystone fasciocutaneous flaps. Right proximal knee closure with full thickness skin graft 18 cm²

THIGH SUBCUTANEOUS MYXOFIBROSARCOMA

- Post op RT
 - CTV1: 1.5 radial and 4 cm proximal, distal margins on the tumor, remainder of operative bed, surgical scar. Only need to extend ~ 5 mm into the muscle since this was subcutaneous tumor
 - CTV2: 1.5 cm radial and 2 cm proximal, distal margins on the tumor
 - PTV expansion: 5 mm using daily cone beam
 - PTV1: 50 Gy/25 fractions, VMAT, no bolus
 - PTV2 boost: 10 Gy boost/5 fractions, VMAT; no bolus

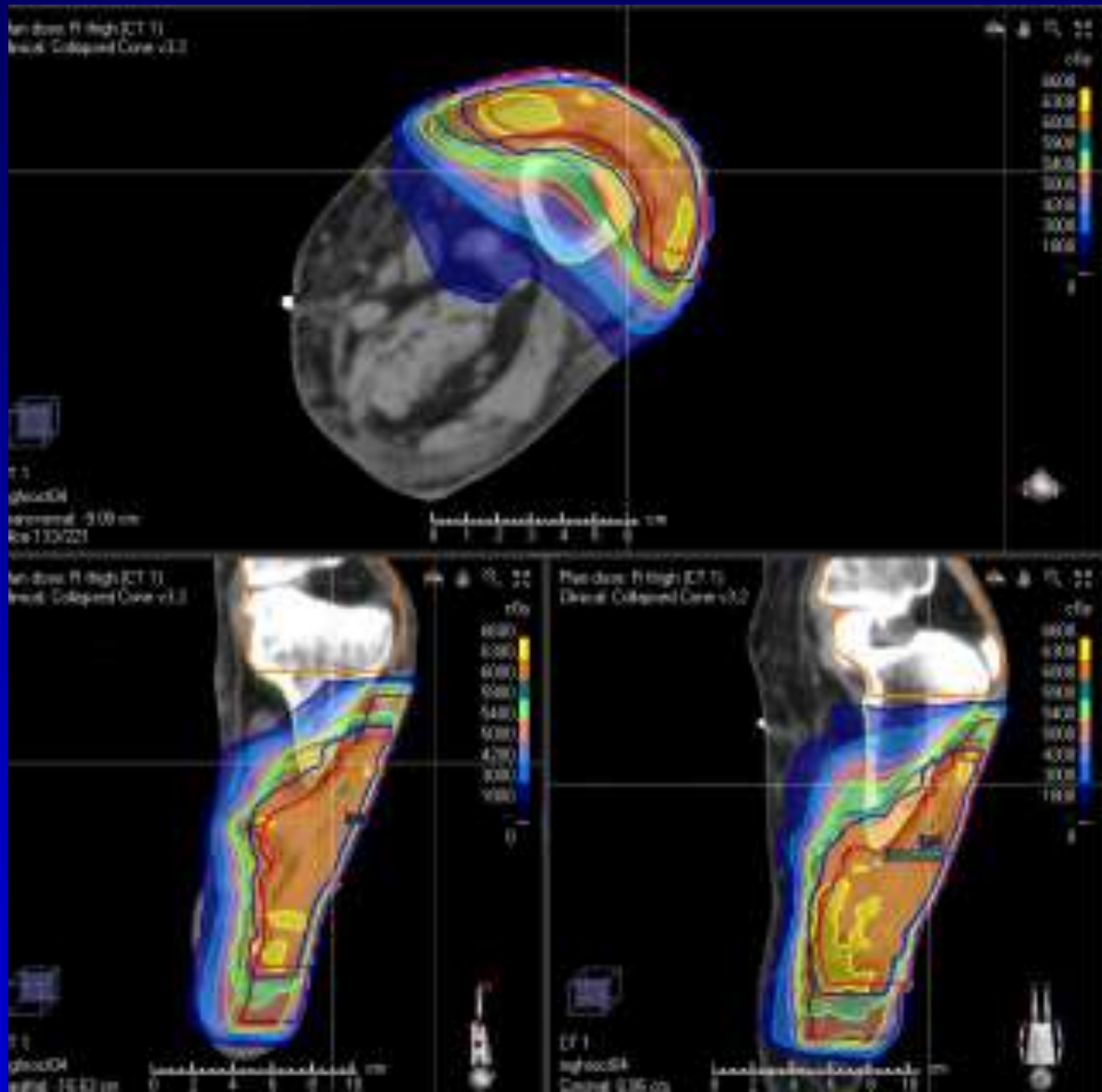
PTV1: 50 Gy/25 fx
VMAT
No bolus



PTV2 boost:
10 Gy/5 fx
VMAT
No bolus



Composite:
60 Gy/30 fx
VMAT
No bolus



Critical Review

Radiotherapy for Management of Extremity Soft Tissue Sarcomas: Why, When, and Where?

Rick L.M. Haas, MD, PhD,^{*} Thomas F. DeLaney, MD, PhD,[†] Brian O'Sullivan, MD, PhD,[‡]
Ronald B. Keus, MD,[§] Cécile Le Pechoux, MD, PhD,^{||} Patricia Olmi, MD, PhD,[¶]
Jan-Peter Poulsen, MD, PhD,[#] Beatrice Seddon, MD, PhD,^{**} and Dian Wang, MD, PhD^{††}

[Int J Radiat Oncol Biol Phys 2012; 84\(3\): 572-580.](#)

